

Plasma Treatment – Results of Skin Microbiome Analysis

Chiharu Watanabe

Chiharu Dermatology, Tokyo, Japan

Correspondence: Chiharu Watanabe, Chiharu Dermatology, 2F Barbizon 86, 5-3-13, Hiroo, Shibuya-ku, Tokyo, 150-0012, Japan, Tel +81334471177, Fax +81334471178, Email chiharu-hifukaclinic@iris.ocn.ne.jp

Purpose: Skin health is deeply linked with the balance of resident bacteria, and a disturbance in this balance can readily cause skin problems. Sterilization with plasma treatment offers potential to improve symptoms in patients with acne vulgaris or atopic dermatitis. The aim of this study was to examine the antibacterial effect of plasma and analyze the correlation between changes in the balance of resident skin bacteria and clinical symptoms following plasma treatment in patients with acne vulgaris or atopic dermatitis.

Patients and Methods: Five patients each with acne vulgaris or atopic dermatitis of moderate severity were treated with plasma irradiation of their face (including lesions) using a nitrogen plasma device called NeoGen Plasma Skin Regeneration. Changes in the resident flora were assessed before and after irradiation using next-generation sequencing.

Results: At 24 hours, the proportion of *Propionibacterium acnes* decreased from 31.2% to 16.2%, and *Staphylococcus epidermidis* increased from 10.8% to 11.7%; in patients with atopic dermatitis, *Staphylococcus aureus* decreased from 4.2% to 2.1%. Across all 10 patients, there was a significant increase in Simpson's Index ($P=0.045$), indicating improvement of the microbiome balance of resident bacteria.

Conclusion: Plasma treatment had a sterilization effect and improved microbiome balance. Larger studies are therefore warranted.

Keywords: plasma treatment, neogen PSR, resident skin bacteria, acne vulgaris, atopic dermatitis

Introduction

With temperature increases, the state of matter changes from solid to liquid to gas, and molecular movement simultaneously becomes more active. Application of further energy to matter in a gaseous state ionizes the atoms by releasing electrons. This state is called plasma, and is more highly activated and has higher energy than the gaseous state. Given that plasma was initially generated at very high temperatures, its application was limited to waste disposal and nuclear fusion. However, in the early 1990s, a sterilization technique utilizing low-temperature plasma of hydrogen peroxide was put to practical use and is now applicable to various fields involved in the handling of heat-sensitive materials – for example, food processing, the living body, and agriculture.

In recent years, applications in healthcare have been of particular interest, and are being actively researched and developed. These include sterilization by low-temperature plasma,¹ hemostasis, surface treatment, sterilization by ultrasonic plasma, and teeth whitening. Since the plasma state is unstable due to the free movement of atomic nuclei, which release ions and electrons, it can easily bind to other matter. This enables the elimination of cuticles and waste on the skin surface by adsorption to plasma and vaporization.

The following effects have been reported in vivo and in vitro:²

1. Skin disinfection and sterilization
2. High transdermal effect (drug delivery)
3. Promotion of heat energy turnover
4. Anti-inflammatory effect
5. Improvement of blood flow
6. Promotion of apoptosis

Skin health is deeply linked to the balance of resident bacteria, and hence a disturbance in this balance can cause skin problems.^{3,4} Based on the properties listed above, plasma has significant potential for the treatment of various skin diseases, including atopic dermatitis, acne vulgaris, acne scars, and skin tumors, as well as for aesthetic rejuvenation.^{5–13}

For example, acne vulgaris is a multifactorial chronic inflammatory disease associated with enhanced sebaceous secretion, hormonal abnormality, dyskeratosis, and inflammation. It is very common in Japan, with an average age of onset of 13 years and a prevalence of almost 60% among young people of secondary school and university age.¹⁴ The condition is caused by *Propionibacterium acnes*, which releases Christie–Atkins–Munch–Petersen (CAMP) factor, inducing inflammation of hair follicles.¹⁵ It is commonly treated using topical formulations such as adapalene, benzoyl peroxide, and antibacterial agents, but is often refractory due to dermatitis and bacterial resistance. In addition, these treatments are sometimes associated with side effects when used long-term.

Atopic dermatitis primarily causes itchy eczema, characterized by repeated exacerbations and remissions. Exacerbations have been associated with *Staphylococcus aureus*.¹⁶ In Japan, prevalence estimates range up to 32% in infants and 15% in school-age children; the estimated prevalence is lower among adults, but remains $\geq 8\%$ in those below 40 years, and the proportion of severe cases is higher among young adults compared with children.¹⁷ Atopic dermatitis is commonly treated using topical steroids and tacrolimus ointments, and other options have recently become available, including JAK inhibitors and biologics. However, common side effects include dermatitis, skin irritation, and worsening of acne.

Thus, there remains a need for novel therapies for both acne vulgaris and atopic dermatitis that are more effective and safe than current options. Plasma treatment is particularly promising because it is minimally invasive, combines antimicrobial and tissue repair effects, has few side effects, and avoids the problem of antibiotic-resistant bacteria.

In our clinic, we have introduced a nitrogen plasma device called NeoGen Plasma Skin Regeneration (PSR) (Energist Ltd, Swansea, United Kingdom). The technology works by converting nitrogen gas to pure nitrogen plasma, which emerges from the handpiece in pulses and delivers controlled heating without creating an open wound. We have used NeoGen PSR for various skin diseases, including acne vulgaris, acne scarring, and atopic dermatitis – as well as lichen pilaris and chloasma, and aesthetic indications like pores, wrinkles, pigmentation, and texture improvement.

Plasma treatment is a noninvasive method for enhancing skin turnover, and has a variety of potential mechanisms of action.^{7,8,12,18} Among various possible effects that may contribute to the improvement of clinical symptoms in patients with acne vulgaris or atopic dermatitis, we have focused on the sterilization effect of plasma.

The aim of the present study was to evaluate the impact of the antimicrobial action of plasma therapy on the balance of indigenous skin bacteria and its relationship with clinical symptoms. This was assessed using next-generation sequencing from lesions in patients with each disease before and after plasma irradiation.

Methods

Study Overview

Five patients with acne vulgaris and 5 with atopic dermatitis were included, each with moderate disease severity according to guidelines from the Japanese Dermatological Association. The study was conducted between June and July 2018. The Medical Ethics Committee of Non-Profit Organization Health Institute Research of Skin granted ethical approval to publish case details (No. IB202404-01). It was confirmed with patients that the details of any images, videos, or recordings could be published. All patients provided written informed consent for publication.

Procedures

One week before irradiation, patients with acne vulgaris discontinued topical and oral medications with antibacterial and anti-inflammatory effects. Similarly, those with atopic dermatitis discontinued topical medications with an anti-inflammatory effect (including topical steroids). Intake of foods that could affect the composition of resident bacteria, such as natto (fermented soybeans) and yogurt, was also prohibited for 1 week before irradiation.

On the morning of the day of plasma irradiation, a skin swab sample of resident bacteria was collected from the sampling region, which was defined as a circle with a 3 cm diameter in the cheek and 1 cm apart from the lower eyelid and the nasal ala, as determined using a specific scale. The patient then washed their face.

Full-face irradiation was performed using NeoGen PSR at an intensity of 0.8 J/cm^2 , followed by iontophoresis of tranexamic acid. Twenty-four hours after irradiation, a second sample of resident bacteria was collected from the same region as previously.

Samples were analyzed using the next-generation sequencer, S-KIN (metagenome analysis, World Fusion Co. Ltd., Tokyo, Japan). Specifically, for the microbiome analysis, DNA samples were fragmented and amplified to read out the V2, 3, 4, 5, 6, 7, 8, and 9 regions of the 16S rRNA gene by Ion PGM sequencer, while eliminating from the analysis any bases of poor quality or read lengths of ≤ 120 base pairs. Total bacterial counts were determined by real-time polymerase chain reaction (PCR) with a Takara Bacteria Quantitative PCR Kit.

Statistical Methods

For mean bacterial counts (*Staphylococcus epidermidis*, *Staphylococcus aureus*, and *Propionibacterium acnes*) before and 24 hours after irradiation, 95% confidence intervals (CI) were calculated. Changes in Simpson's Index (a diversity index of resident skin bacteria) over the same time period were assessed using a paired *t*-test. Analyses were performed using the S-KIN software.

Results

Changes in the primary microbiome were analyzed over time for 24 hours after plasma irradiation using S-KIN metagenome analysis. The proportion of *Propionibacterium acnes* decreased from 31.2% (95% CI: 8.8, 53.5) to 16.2% (95% CI: 4.3, 28.2) (Figure 1), and for *Staphylococcus epidermidis*, it increased from 10.8% (95% CI: 2.3, 19.4) to 11.7% (95% CI: 3.7, 19.7) (Figure 2). *Staphylococcus aureus* was assessed in the 5 patients with atopic dermatitis, and was found to have decreased from 4.2% (95% CI: -1.7, 10.1) to 2.1% (95% CI: -1.2, 5.3) (Figure 3).

Four case examples are provided in Figures 4–7. Case 1 was a 31-year-old woman with acne vulgaris who had pustules and papulae on the whole of her forehead, cheeks, and jaw. She showed improvement after irradiation without new symptoms (Figure 4A). Within 24 hours, the proportion of *Propionibacterium acnes* in the total bacterial count decreased from 5% to 4% (Figure 4B).

Case 2 was a 23-year-old woman with acne vulgaris who had pustules and papulae on the whole of her forehead and cheeks. She showed improvement after irradiation (Figure 5A). After 24 hours, the proportion of *Propionibacterium acnes* markedly decreased from 74% to 36% (Figure 5B).

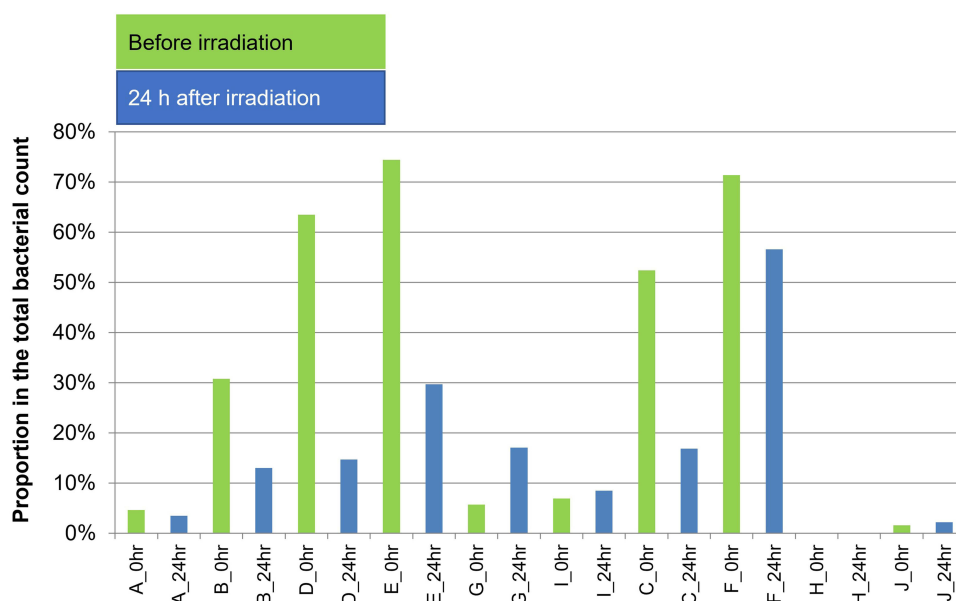


Figure 1 Changes in primary bacterial species over time: *Propionibacterium acnes*. The figure shows results from swab samples before irradiation and at 24 hours after irradiation.

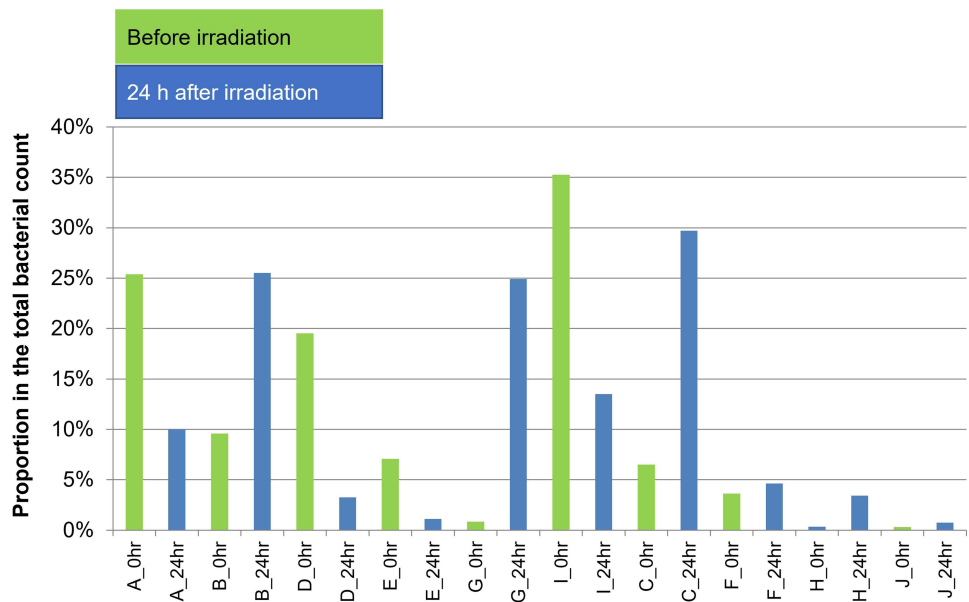


Figure 2 Changes in primary bacterial species over time: *Staphylococcus epidermidis*. The figure shows results from swab samples before irradiation and at 24 hours after irradiation.

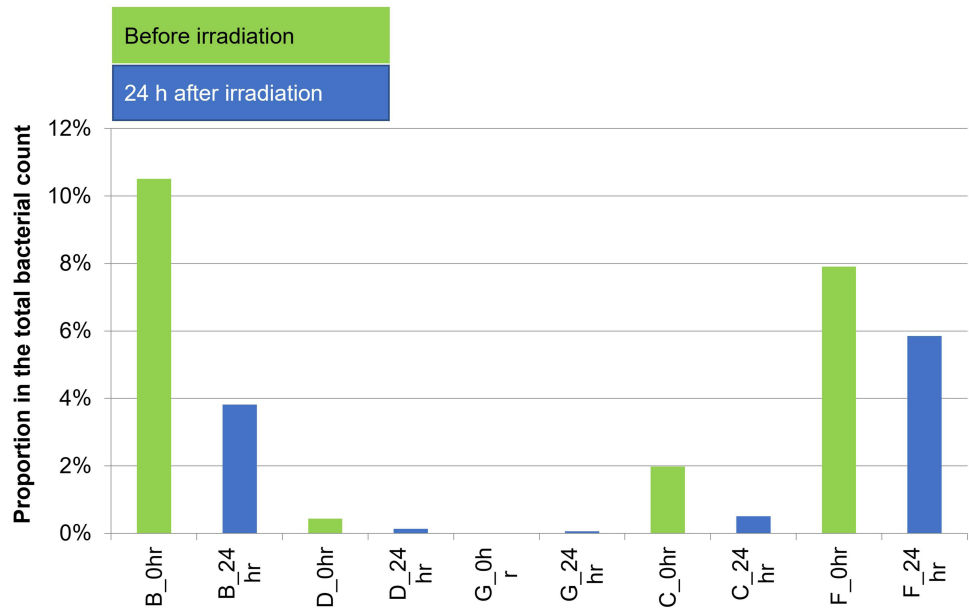


Figure 3 Changes in primary bacterial species over time in patients with atopic dermatitis: *Staphylococcus aureus*. The figure shows results from swab samples before irradiation and at 24 hours after irradiation.

Case 3 was a 36-year-old man who had had atopic dermatitis since childhood. Following irradiation, he showed improvement of diffuse erythema on the whole face, as well as smoother skin (Figure 6A). Within 24 hours, the proportion of *Staphylococcus aureus* decreased from 11% to 4%, and the proportion of *Staphylococcus epidermidis* increased from 10% to 26% (Figure 6B).

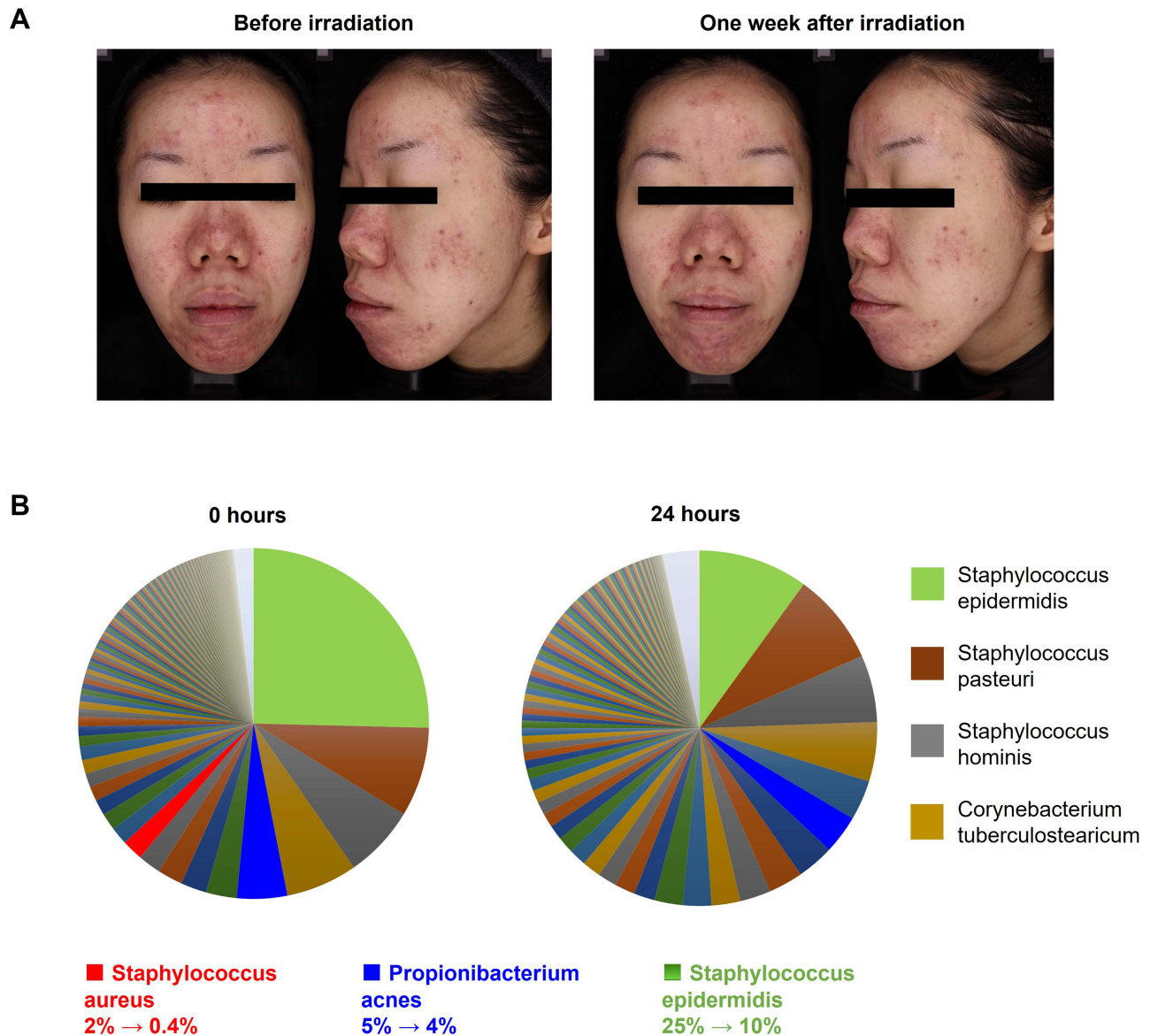


Figure 4 A 31-year-old woman with acne vulgaris. (A) Shows the patient before and 1 week after treatment. (B) Shows changes in all bacterial species at 0 and 24 hours.

Case 4 was a 44-year-old woman with atopic dermatitis since childhood who had used topical steroids for a long time, which induced a complication of cataract. After irradiation, the clinical symptoms improved not only for erythema and dryness but also for skin texture, resulting in smoother skin (Figure 7A). Within 24 hours, the proportion of *Staphylococcus aureus* decreased from 8% to 6% (Figure 7B).

Across the 10 included patients, analysis of bacterial counts using real-time PCR showed decreases in all three bacterial species at 24 hours after plasma irradiation (Table 1). There were particularly meaningful reductions in *Propionibacterium acnes* and *Staphylococcus aureus*. Furthermore, Simpson's Index – a diversity index of resident skin bacteria – significantly increased within 24 hours ($P=0.045$), indicating improvement of the microbiome balance of resident bacteria (Table 2).

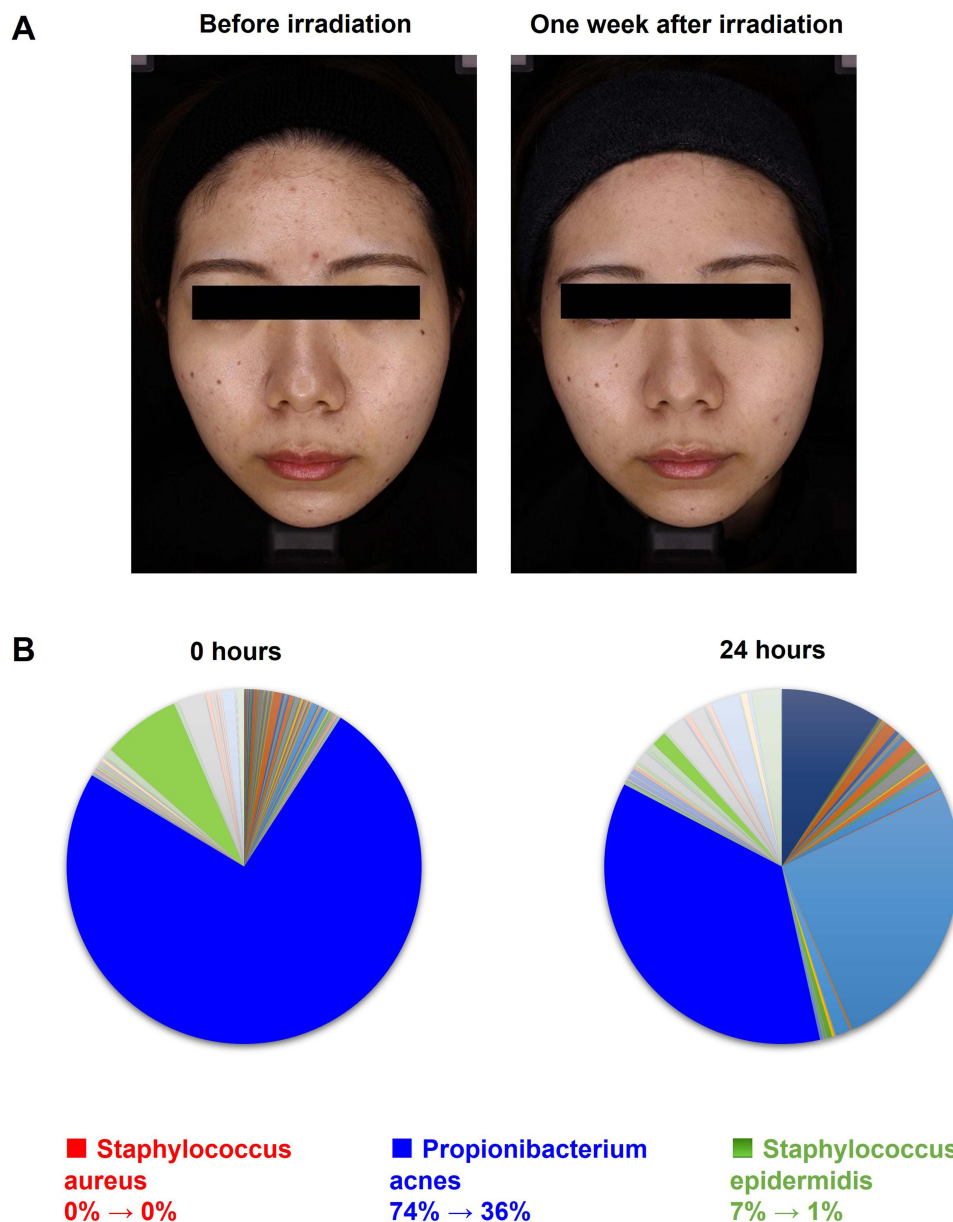


Figure 5 A 23-year-old woman with acne vulgaris. (A) Shows the patient before and 1 week after treatment. (B) Shows changes in all bacterial species at 0 and 24 hours.

Discussion

Applying heat to a gas at thousands of degrees Celsius ionizes the molecules into positive ions and electrons that can move freely; this is plasma, considered as a fourth state of matter. In recent years, there has been significant interest in potential applications within the healthcare field. Since the 1990s, low-temperature sterilization using various types of plasma has been vigorously studied, for example based on low-pressure discharge plasma^{19–29} and atmospheric pressure discharge plasma.^{30–35} The principle of plasma sterilization is that highly reactive radicals created by the collision of high-energy electrons with atoms and molecules in plasma chemically react with cells to kill bacteria. In addition, bacterial death may be caused by damage to cellular DNA from ultraviolet rays emitted from atoms excited by the high-energy electrons, as well as the direct collision with cells of discharged particles, such as electrons and ions.

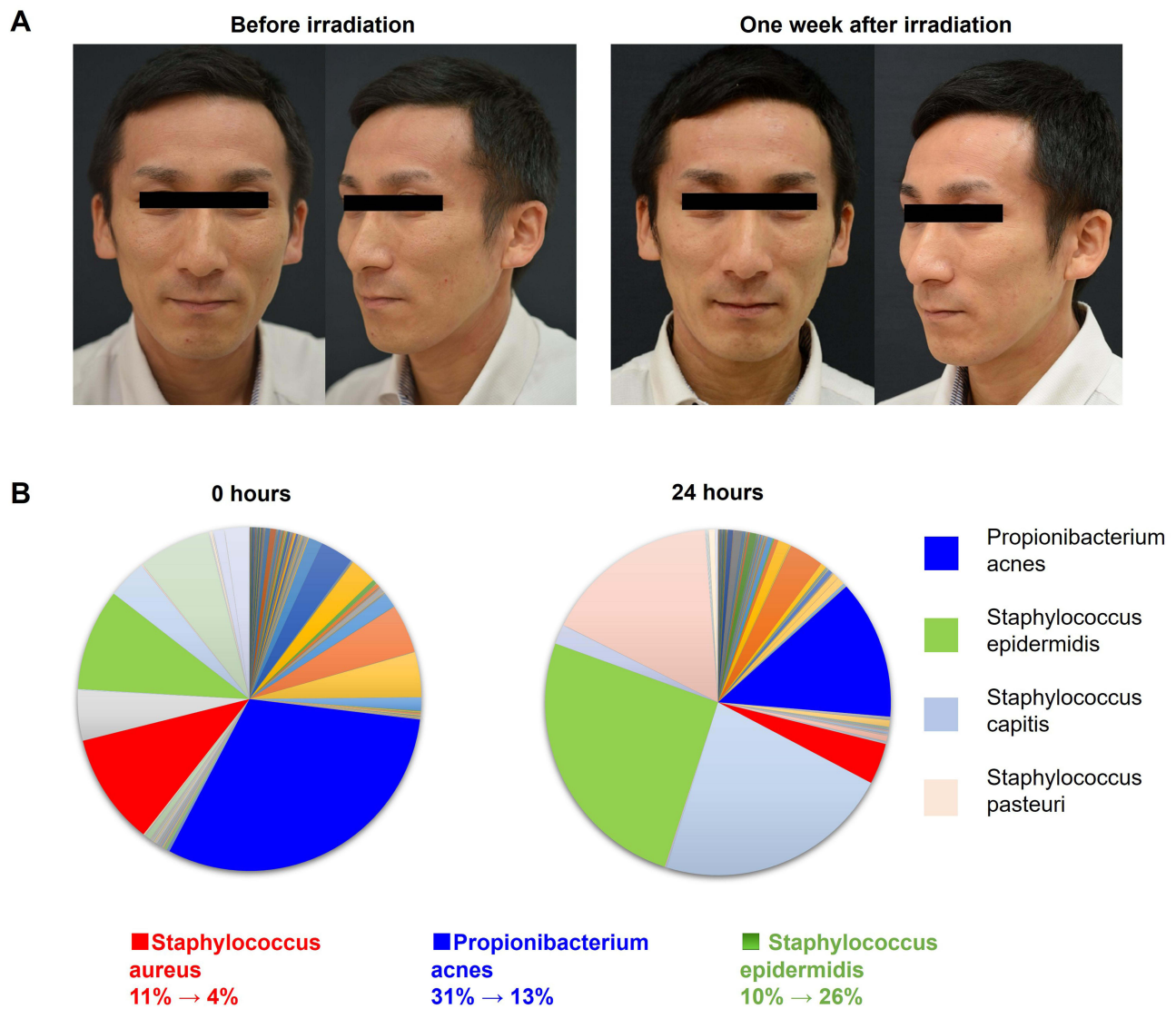


Figure 6 A 36-year-old man with atopic dermatitis. (A) Shows the patient before and 1 week after treatment. (B) Shows changes in all bacterial species at 0 and 24 hours.

In dermal diseases, plasma treatments may be used for skin disinfection and sterilization, transdermal effects (drug delivery), promotion of heat energy turnover, anti-inflammatory effects, blood flow improvement, promotion of apoptosis (as well as a cancer cell reduction¹), skin rejuvenation,^{7,8,13} and scar treatment.^{36–38} In the optically damaged layer produced by plasma irradiation, the epidermis remains intact and forms a thin crust that acts as a natural dressing to promote healing of heat injury in the dermis and lower layers.

In our practice, we use the nitrogen gas plasma device, NeoGen PSR, to achieve good results in various indications, including atopic dermatitis, acne vulgaris, acne scarring, post-inflammatory pigmentation, and wrinkle treatment. Treatment benefit may be induced by the combined effects described above.

In the present study, we focused on the correlation between plasma sterilization effects and improvements in skin symptoms, and observed changes in the facial microbiome before and after irradiation – analyzed by next-generation sequencing and clinical findings. The bacterial component of acne development is familiar within the dermatologic field. However, in recent years, abnormal balances of the microbiome constituting resident flora have been linked with the development of other common concerns, such as allergy and autoimmune diseases.^{3,4}

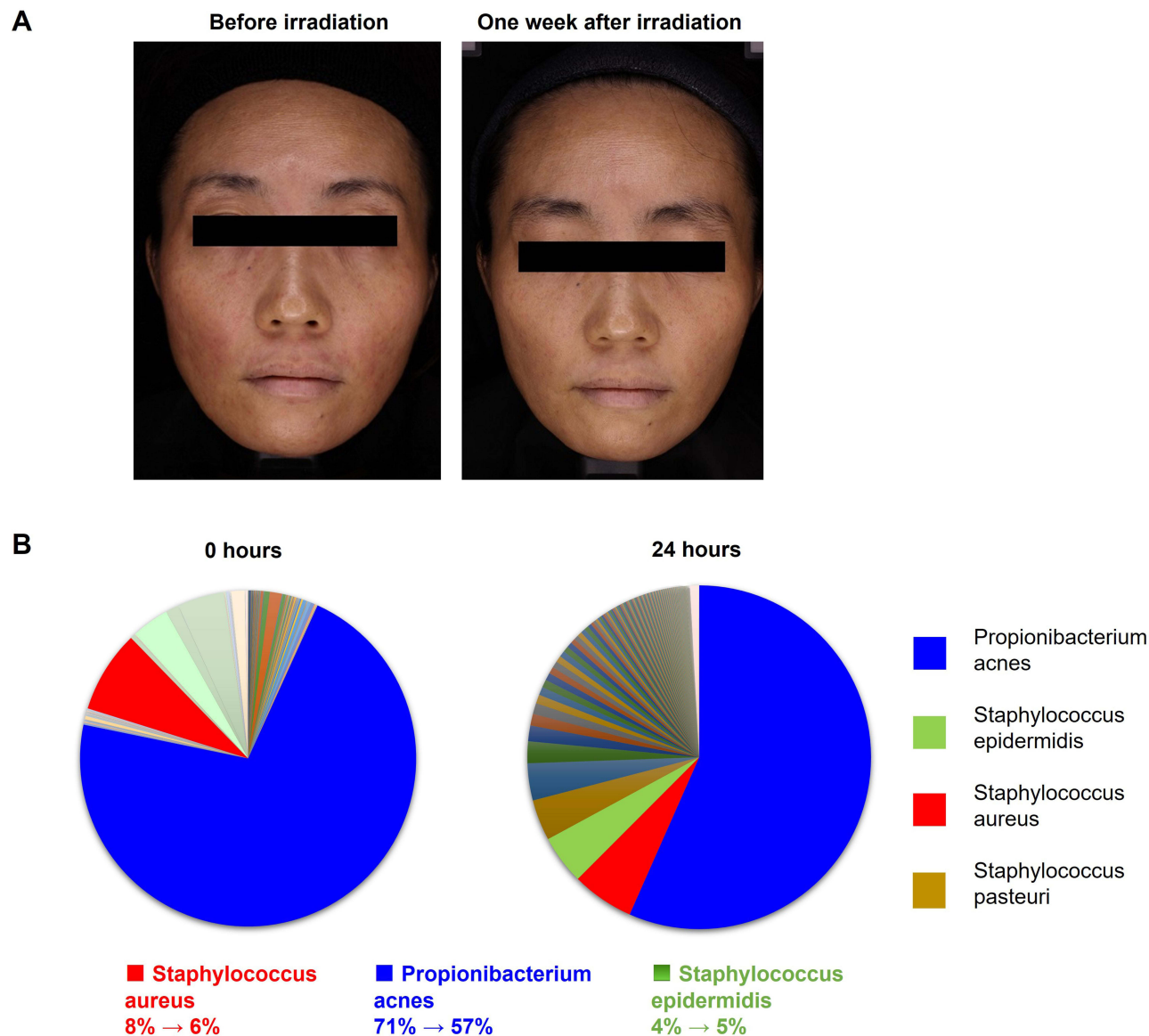


Figure 7 A 44-year-old woman with atopic dermatitis. **(A)** Shows the patient before and 1 week after treatment. **(B)** Shows changes in all bacterial species at 0 and 24 hours.

Resident bacteria on skin include *Staphylococcus epidermidis*, *Propionibacterium acnes*, and *Staphylococcus aureus*.¹⁶ *Staphylococcus epidermidis* is found on the surface of the epidermis and pores;³⁹ it is considered to feed on sweat (alkaline) and sebum to produce glycerin and fatty acids,⁴⁰ keep the skin mildly acidic,⁴¹ avoid proliferation of *Staphylococcus aureus* by producing antibacterial peptides, and maintain skin barrier function.⁴²

Table 1 Changes in Bacterial Counts Before and After Irradiation as Determined by Real-Time PCR

Bacteria Name	Mean Diversity Index at 0 h	Mean Diversity Index at 24 h
Staphylococcus epidermidis	1769	1452
Propionibacterium acnes	6271	1274
Staphylococcus aureus	544	200

Abbreviation: PCR, polymerase chain reaction.

Table 2 Diversity Index of Resident Skin Bacteria

	Mean Diversity Index at 0 h	Mean Diversity Index at 24 h	P value (0 h vs 24 h; Paired t-test)
Simpson's Index	0.734	0.845	0.045

Propionibacterium acnes is an anaerobic bacterium found in the pores and sebaceous glands, and may feed on sebum to produce propionic acid and fatty acids, keep the skin mildly acidic, and inhibit the proliferation of highly pathogenic bacteria.⁴³ It is generally considered to be a key cause of acne vulgaris. Excess proliferation of *Propionibacterium acnes* may result from increased sebum secretion and plugged pores as a result of this or of dyskeratosis.

Staphylococcus aureus is found on the skin surface and pores,^{44,45} and is considered to induce dermatitis by proliferation on alkaline skin.⁴⁶

In recent years, gene decoding technology has advanced as a result of next-generation sequencing, which enables exhaustive investigation of the microbiome through analysis of bacterial 16S rRNA. A microbiome analysis in atopic dermatitis found that the composition of the skin flora changed dramatically, with a significant increase of *Staphylococcus aureus*.⁴⁷

In our study of a nitrogen gas plasma treatment device in patients with acne vulgaris or atopic dermatitis, counts of *Propionibacterium acnes* and *Staphylococcus aureus* decreased while *Staphylococcus epidermidis* increased in some cases. Furthermore, there was a recovery in the diversity of resident skin flora. Case studies showed that patients experienced parallel improvements in symptoms. The reasons for this may have been decreases in causal bacteria (*Propionibacterium acnes* inducing inflammation in acne vulgaris, and *Staphylococcus aureus* in atopic dermatitis), as well as improvements in the balance of resident skin bacteria.

We must acknowledge the limitations of the present study. In particular, the sample size was small and the follow-up period lasted only a few days. Nonetheless, the positive results achieved provide a rationale for larger multicenter studies of longer duration, which will be needed to conclusively demonstrate the impact of plasma treatment in these patients. Additional research is also required to explore the utility of combining it with other standard treatments (eg topical steroids, antibacterials, and biologics).

In the long-term, plasma treatment may offer the possibility of regulating indigenous skin bacteria to a more balanced composition and promoting the restoration of skin barrier function. Further studies are needed to assess such changes in barrier function, as well as the immune response and the process of recovery of the indigenous microbiota. These would provide a more definitive assessment of the safety and efficacy of plasma treatment. Another important research area will be to analyze how persistent changes in specific skin microbiota affect the risk of recurrence of inflammatory diseases.

Conclusion

In this pilot study in 10 patients with acne vulgaris or atopic dermatitis, plasma treatment not only had a sterilization effect but also improved the microbiome balance of resident skin bacteria. This has potential to physically and physiologically improve skin barrier function by regenerating the keratinous layer, resulting in the improvement of skin symptoms in acne vulgaris and atopic dermatitis. Larger studies are therefore warranted.

Consent for Publication

We have confirmed with the patients that the details of any images, videos, recordings, etc can be published. Patients' informed consent for publication of their case details and images was obtained in written form. The Medical Ethics Committee of Non-Profit Organization Health Institute Research of Skin has granted ethical approval for this study to publish case details (No. IB202404-01).

Disclosure

The author reports no conflicts of interest in this work.

References

1. Nagatsu M. Plasma sterilization. *J Plasma Fusion Res.* 2007;83(7):601–606.
2. Bernhardt T, Semmler ML, Schafer M, et al. Plasma medicine: applications of cold atmospheric pressure plasma in dermatology. *Oxid Med Cell Longev.* 2019;2019:3873928. doi:10.1155/2019/3873928
3. Kong HH, Andersson B, Clavel T, et al. Performing skin microbiome research: a method to the madness. *J Invest Dermatol.* 2017;137(3):561–568. doi:10.1016/j.jid.2016.10.033
4. Loomis KH, Wu S, Emlund A, et al. A mixed community of skin microbiome representatives influences cutaneous processes more than individual members. *Microbiome.* 2021;9(1):22. doi:10.1186/s40168-020-00963-1
5. Lee MH, Lee YS, Kim HJ, et al. Non-thermal plasma inhibits mast cell activation and ameliorates allergic skin inflammatory diseases in NC/Nga mice. *Sci Rep.* 2019;9(1):13510. doi:10.1038/s41598-019-49938-9
6. Choi JH, Song YS, Lee HJ, et al. Inhibition of inflammatory reactions in 2,4-dinitrochlorobenzene induced Nc/Nga atopic dermatitis mice by non-thermal plasma. *Sci Rep.* 2016;6(1):27376. doi:10.1038/srep27376
7. Bogle MA, Arndt KA, Dover JS. Evaluation of plasma skin regeneration technology in low-energy full-facial rejuvenation. *Arch Dermatol.* 2007;143(2):168–174. doi:10.1001/archderm.143.2.168
8. Kilmer S, Semchysyn N, Shah G, et al. A pilot study on the use of a plasma skin regeneration device (Portrait PSR3) in full facial rejuvenation procedures. *Lasers Med Sci.* 2007;22(2):101–109. doi:10.1007/s10103-006-0431-9
9. Potter MJ, Harrison R, Ramsden A, et al. Facial acne and fine lines: transforming patient outcomes with plasma skin regeneration. *Ann Plast Surg.* 2007;58(6):608–613. doi:10.1097/01.sap.0000252481.84134.fe
10. Gonzalez MJ, Sturgill WH, Ross EV, et al. Treatment of acne scars using the plasma skin regeneration (PSR) system. *Lasers Surg Med.* 2008;40(2):124–127. doi:10.1002/lsm.20617
11. Fitzpatrick R, Bernstein E, Lye S, et al. A histopathologic evaluation of the plasma skin regeneration system (PSR) versus a standard carbon dioxide resurfacing laser in an animal model. *Laser Surg Med.* 2008;40(2):93–99. doi:10.1002/lsm.20547
12. Foster KW, Moy RL, Fincher EF. Advances in plasma skin regeneration. *J Cosmet Dermatol.* 2008;7(3):169–179. doi:10.1111/j.1473-2165.2008.00385.x
13. Holcomb JD, Kent KJ, Rouso DE. Nitrogen plasma skin regeneration and aesthetic facial surgery: multicenter evaluation of concurrent treatment. *Arch Facial Plast Surg.* 2009;11(3):184–193. doi:10.1001/archfaci.2009.29
14. Hayashi N, Kawashima M, Watanabe S, et al. An epidemiological study of acne vulgaris in Japan by questionnaire. *Japanese J Dermatol.* 2001;111(9):1347–1355.
15. Dekio I, Culak R, Fang M, Ball G, Gharbia S, Shah HN. Correlation between phylogroups and intracellular proteomes of *Propionibacterium acnes* and differences in the protein expression profiles between anaerobically and aerobically grown cells. *Biomed Res Int.* 2013;2013:151797. doi:10.1155/2013/151797
16. Kobayashi T, Glatz M, Horiuchi K, et al. Dysbiosis and staphylococcus aureus colonization drives inflammation in atopic dermatitis. *Immunity.* 2015;42(4):756–766. doi:10.1016/j.immuni.2015.03.014
17. Saeki H, Ohya Y, Arakawa H, et al. English version of clinical practice guidelines for the management of atopic dermatitis 2024. *J Dermatol.* 2025;52(2):e70–e142. doi:10.1111/1346-8138.17544
18. Gentile RD, McCoy JD. Pulsed and fractionated techniques for helium plasma energy skin resurfacing. *Facial Plast Surg Clin North Am.* 2020;28(1):75–85. doi:10.1016/j.fsc.2019.09.007
19. Moisan M, Barbeau J, Moreau S, Pelletier J, Tabrizian M, Yahia LH. Low-temperature sterilization using gas plasmas: a review of the experiments and an analysis of the inactivation mechanisms. *Int J Pharm.* 2001;226(1–2):1–21. doi:10.1016/S0378-5173(01)00752-9
20. Tamazawa K. Characteristics and problems of plasma sterilization, and future prospects for new plasma sterilization. *J Antibacterial Antifungal Agents.* 2004;32:13–30.
21. Khomich VA, Soloshenko IA, Tsiolko VV, Mikhno IL. Cold sterilization of medical devices and materials by plasma DC glow discharge. Proceedings of the XII International Conference on Gas Discharges and Their Applications. Greifswald, Germany. 1997;2:740.
22. Soloshenko IA, Tsiolko VV, Khomich VA, et al. Sterilization of medical products in low-pressure glow discharges. *Plasma Phys Report.* 2000;26(9):792. doi:10.1134/1.1309476
23. Philip N, Saoudi B, Crevier MC, Moisan M, Barbeau J, Pelletier J. The respective roles of UV photons and oxygen atoms in plasma sterilization at reduced gas pressure: the case of N₂/O₂ mixtures. *IEEE Trans Plasma Science.* 2002;30(4):1429. doi:10.1109/TPS.2002.804203
24. Moisan M, Saoudi B, Crevier MC, et al. Microwave discharges: fundamentals and applications. Proceedings of the 5th International Workshop on Microwave Discharges: Fundamentals and Applications. Greifswald, Germany. July 8–12, 2003:210.
25. Feichtinger J, Schulz A, Walker M, Schumacher U. Sterilisation with low-pressure microwave plasmas. *Surf Coat Technol.* 2003;564:174–175.
26. Nagatsu M, Terashita F, Koide Y. Low-temperature sterilization with surface-wave-excited oxygen plasma. *Jpn J Appl Phys.* 2003;42(7B):L856.
27. Nagatsu M, Terashita F, Nonaka H, Xu L, Nagata T, Koide Y. Effects of oxygen radicals in low-pressure surface-wave plasma on sterilization. *Appl Phys Lett.* 2005;86(21):211502. doi:10.1063/1.1931050
28. Hayashi N, Guan W, Tsutsui S, Tomari T, Hanada Y. Sterilization of medical equipment using radicals produced by oxygen/water vapor RF plasma. *Jpn J Appl Phys.* 2006;45(10S):8358. doi:10.1143/JJAP.45.8358
29. Kylian O, Sasaki T, Rossi F. Plasma sterilization of *Geobacillus stearothermophilus* by O₂/N₂ RF inductively coupled plasma. *Eur Phys Appl Phys.* 2006;34(2):139. doi:10.1051/epjap:2006034
30. Laroussi M, Alexeff I, Kang WL. Biological decontamination by nonthermal plasmas. *IEEE Trans Plasma Sci.* 2000;28(1):184. doi:10.1109/27.842899
31. Montie TC, Kelly-Wintenberg K, Roth JR. An overview of research using the one atmosphere uniform glow discharge plasma (OAUGDP) for sterilization of surfaces and materials. *IEEE Trans Plasma Sci.* 2000;28(1):41. doi:10.1109/27.842860
32. Park BJ, Lee DH, Park JC, et al. Sterilization using a microwave-induced argon plasma system at atmospheric pressure. *Phys Plasmas.* 2003;10(11):4539. doi:10.1063/1.1613655
33. Akitsu T, Ohkawa H, Tsuji M, Kimura H, Kogoma M. Plasma sterilization using glow discharge at atmospheric pressure. *Surf Coat Technol.* 2005;193(1–3):29. doi:10.1016/j.surfcoat.2004.07.042

34. Yu QS, Huang C, Hsieh FH, Huff H, Duan Y. Sterilization effects of atmospheric cold plasma brush. *Appl Phys Lett*. 2005;86:013903.
35. Laroussi M. Low temperature plasma-based sterilization: overview and state-of-the-art. *Plasma Process Polym*. 2005;2(5):391. doi:10.1002/ppap.200400078
36. Higashimori T, Kono T, Sakurai H, et al. Treatment of mesh skin grafted scars using a plasma skin regeneration system. *Plast Surg Int*. 2010;2010:874348. doi:10.1155/2010/874348
37. Kono T, Groff WF, Sakurai H, et al. Treatment of traumatic scars using plasma skin regeneration (PSR) system. *Lasers Surg Med*. 2009;41(2):128–130. doi:10.1002/lsm.20723
38. Groff WF, Fitzpatrick RE, Uebelhoefer NS. Fractional carbon dioxide laser and plasmakinetic skin resurfacing. *Semin Cutan Med Surg*. 2008;27(4):239–251. doi:10.1016/j.sder.2008.10.002
39. Claudel J, Auffret N, Leccia M, et al. *Staphylococcus epidermidis*: a potential new player in the physiopathology of acne? *Dermatology*. 2019;235(4):287–294. doi:10.1159/000499858
40. Dreno B, Dagnelie M, Khammari A, et al. The skin microbiome: a new actor in inflammatory acne. *Am J Clin Dermatol*. 2020;21(Suppl 1):18–24. doi:10.1007/s40257-020-00531-1
41. Nodake Y, Matsumoto S, Miura R, et al. Pilot study on novel skin care method by augmentation with *Staphylococcus epidermidis*, an autologous skin microbe—a blinded clinical trial. *J Dermatol Sci*. 2015;79(2):119–126. doi:10.1016/j.jdermsci.2015.05.001
42. Baviera G, Leoni M, Capra L, et al. Microbiota in healthy skin and in atopic eczema. *Biomed Res Int*. 2014;2014:436921.
43. Dreno B, Pecastaings S, Corvec S, et al. *Cutibacterium acnes* (*Propionibacterium acnes*) and acne vulgaris: a brief look at the latest updates. *J Eur Acad Dermatol Venereol*. 2018;32(Suppl 2):5–14. doi:10.1111/jdv.15043
44. Broeke-Smits N, Kummer J, Bleys R, et al. Hair follicles as a niche of *Staphylococcus aureus* in the nose; is a more effective decolonization strategy needed? *J Hosp Infect*. 2010;76(3):211–214. doi:10.1016/j.jhin.2010.07.011
45. Laureano A, Schwartz R, Cohen P. Facial bacterial infections: folliculitis. *Clin Dermatol*. 2014;32(6):711–714. doi:10.1016/j.clindermatol.2014.02.009
46. Proksch E. pH in nature, humans and skin. *J Dermatol*. 2018;45(9):1044–1052. doi:10.1111/1346-8138.14489
47. Kong HH, Oh J, Deming C, et al. Temporal shifts in the skin microbiome associated with disease flares and treatment in children with atopic dermatitis. *Genome Res*. 2012;22(5):850–859. doi:10.1101/gr.131029.111

Clinical, Cosmetic and Investigational Dermatology

Publish your work in this journal

Clinical, Cosmetic and Investigational Dermatology is an international, peer-reviewed, open access, online journal that focuses on the latest clinical and experimental research in all aspects of skin disease and cosmetic interventions. This journal is indexed on CAS. The manuscript management system is completely online and includes a very quick and fair peer-review system, which is all easy to use. Visit <http://www.dovepress.com/testimonials.php> to read real quotes from published authors.

Submit your manuscript here: <https://www.dovepress.com/clinical-cosmetic-and-investigational-dermatology-journal>

Dovepress
Taylor & Francis Group